

# Leg Ulcer Pain Relief Prior to Punch Biopsy Treatment

Deborah Hofman Clinical nurse Specialist, Dermatology Unit, Churchill Hospital, Oxford.

## The Patient

Mr. R is an 86 year old man with history of recurrent leg ulceration since 1990. He lives at home with his wife who is fit, well and very supportive. Mr. R, however does not enjoy good health. He suffers from ulcerative colitis, Duke's B adenocarcinoma to the splenic flexure and underwent a left hemicolectomy in 1992. He had a coronary artery bypass graft in January 2003 and a left superficial femoral artery angioplasty in August 2004.

## The Ulcer

Following the angioplasty there was some initial reduction in ulcer size but by March 2005 the ulcer was extending and becoming more painful. I took over his care a month later when he was reporting pain of level 8 that was worse at night causing him to sleep badly. He also complained of claudication pain at 30 yards. Doppler examination gave an ABPI of 0.68.

The ulcer is situated on the lateral aspect of his left leg above the malleolus and measured 5x3 cms. The wound bed was pale with some slough. (Figure 1)

## Treatment with ActiFormCool®

ActiFormCool® was applied and gave immediate pain relief. When Mr R was seen 3 days after initial application he reported no pain in his ulcer, no pain at night and was only troubled by pain in his calf when walking. In addition the ulcer bed had become red and granulating with no appearance of slough. (Figure 2). The ulcer remained clean and began slowly to reduce in size. Medlock was used for support until he had been reviewed by the vascular unit.

It was decided to admit Mr. R for punch grafting of his ulcer which took place on 2nd August 2005. The dressing was taken down 1 week later showing good graft take (Figure 3). The week prior to grafting Mr R had been re-referred to the vascular unit for a further arterial duplex scan. This showed no significant arterial disease in his left leg and compression was recommended. Actico short stretch bandaging (Activa Healthcare) was applied and was well tolerated following grafting. He is currently being followed up in the leg ulcer clinic on a weekly basis and the ulcer continues to heal well.

## Conclusion

ActiFormCool® gave immediate and continuous ulcer pain relief allowing Mr. R to get a good night's rest. In addition the dressing appeared to promote debridement and granulation providing an ideal wound bed for punch grafts to be applied.

“Wound dressings can have a profound effect on the repair process and patient quality of life”

Kerstein (1995)

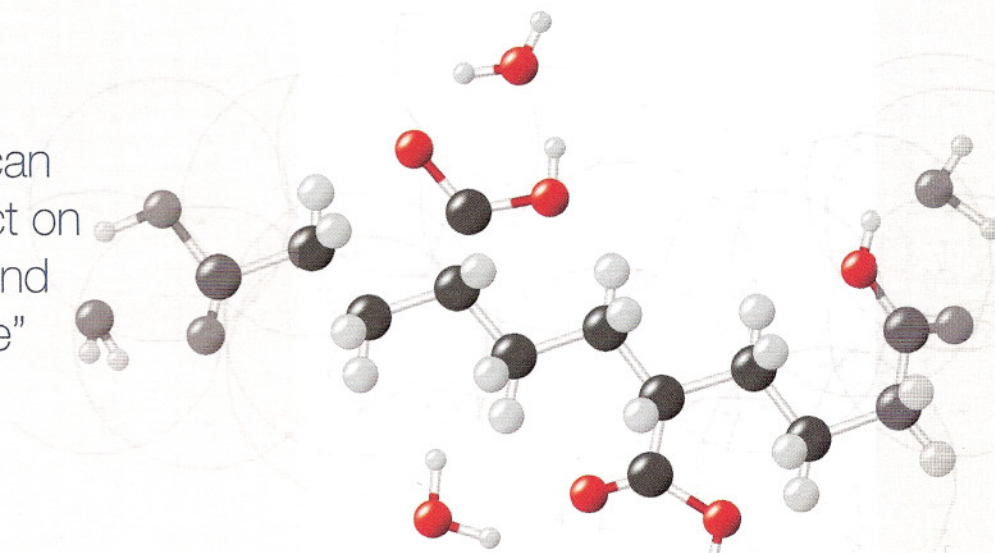

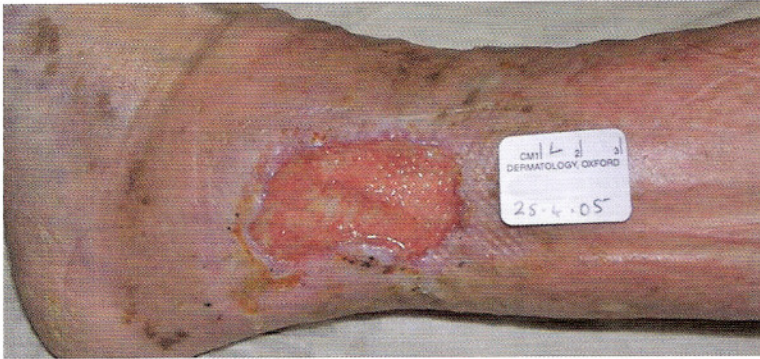


Figure 1  
Mr R's leg ulcer before treatment showing a pale wound bed with some slough present

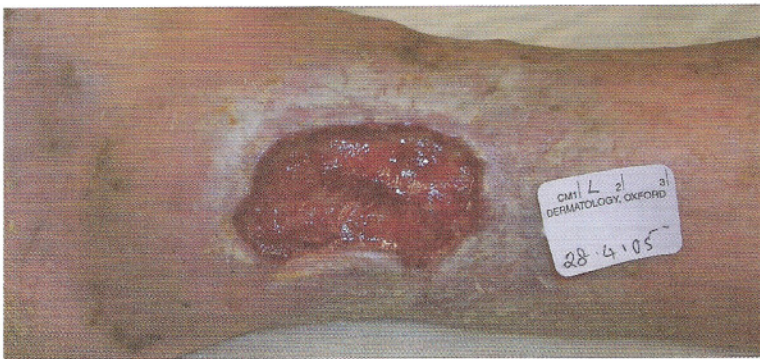


Figure 2  
After 3 days treatment with ActiFormCool there was no pain and the ulcer bed was red and granulating with no evidence of slough

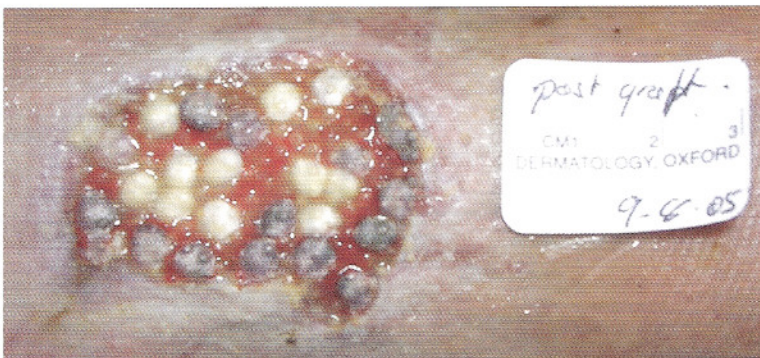

Figure 3  
The ulcer showing good punch graft take



“Taking the safest form of  
wound debridement and  
speeding it up”

Sylvie Hampton.MA BSc (Hons) DpSN RGN,  
Tissue Viability Consultant, Dental Practice Board,  
Eastbourne.